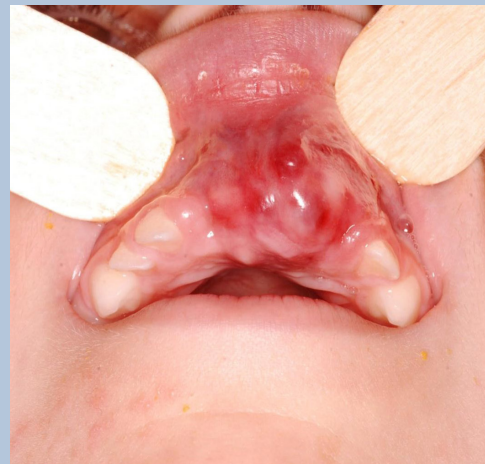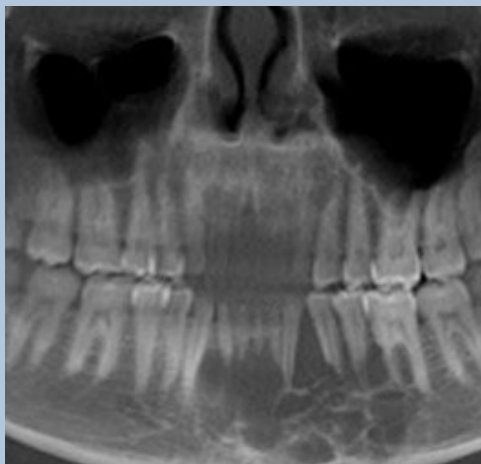

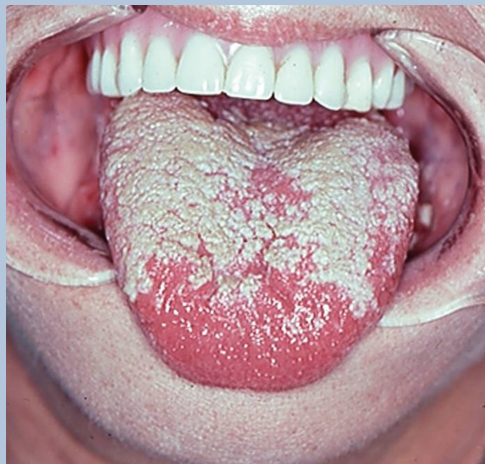
Webinars in Oral and Maxillofacial Surgery Pathology and Reconstruction

RECORDED SESSIONS

MAY 2015 – MARCH 2016



KEYNOTE SPEAKER



Robert E. Marx, DDS
Professor of Surgery
Chief Division of Oral
and Maxillofacial Surgery
University of Miami
Miller School of Medicine

MODERATOR

Lawrence Armentano, DDS, MD
Assistant Professor of Surgery
Chief Medical Education Division
of Oral and Maxillofacial Surgery
University of Miami Miller School
of Medicine

GUEST CO-PRESENTERS

Diane Stern, DDS
Adjunct Professor of Surgery and
Chief of Oral & Maxillofacial Pathology
University of Miami Miller School
of Medicine

Ramzey Tursun, DDS
Assistant Professor of Surgery
Chief of Microvascular Surgery
University of Miami Miller
School of Medicine

Description

Ten monthly one hour webcasts starting in May 2015 and continuing through to March 2016. Three cases will be reviewed in the case presentation format of Case Based learning. Fifteen minutes per case with a following five minutes of questions and answers (Q & A) from typed in questions by registrants. The moderator will choose the best questions and propose them to the host and/or guest speakers. The moderator may also pose his own direct questions.

Objectives

Upon completion of the each webinar participants will be able to:

1. Gain a level of knowledge related to the appropriate workup, differential diagnosis and direct treatment of pathologic conditions from real case presentations.
2. Understand the various choices in bony and soft tissue reconstruction available today.
3. Stimulate members of the oral and maxillofacial surgery specialty and other specialties of dentistry to become more involved in the diagnosis and direct treatment of people with real disease entities.
4. Accurately case plan and deliver specific treatment options which will improve patient outcomes.



R E C O R D E D S E S S I O N S

May 7, 2015

1. Late tumor formation arising from an unremoved wisdom tooth
2. Pathologic fracture in a patient taking an IV bisphosphonate
3. Child with a multilocular radiolucent lesion of the mandible

June 11, 2015

1. Horizontal ridge augmentation using recombinant human bone morphogenetic protein and allogeneic bone
2. Cherubism diagnosis and treatment planning
3. Ramon syndrome

July 16, 2015

1. Ameloblastoma of the maxilla
2. Exposed bone in a patient taking an oral bisphosphonate
3. Rescuing a deficient fibula graft

August 13, 2015

1. Dermoid cyst in the anterior neck
2. Osteoradionecrosis with a pathologic fracture
3. Sinus lift graft using allogeneic bone, PRP, and rhBMP-2/ACS

September 17, 2015

1. Broken titanium plate in a patient with a continuity defect of the mandible
2. Extreme size ameloblastoma of the mandible
3. Squamous cell carcinoma of the lower lip

October 22, 2015

1. Exposed bone in a patient receiving denosumab for prostate cancer
2. Osteomyelitis and a pathologic fracture after wisdom tooth removal
3. Schwannoma of the infratemporal space

November 12, 2015

1. Mylodysplastic syndrome in a patient with an exposed plate
2. Florid cemento osseous dysplasia
3. Black hairy tongue

December 10, 2015

1. Major complication of dental implant placement
2. Palatal tumor differential diagnosis and treatments
3. Lump in the neck

February 11, 2016

1. Ameloblastoma of the mandible with immediate reconstruction
2. Squamous cell carcinoma of the mandible resection with microvascular reconstruction
3. Dental implant rehabilitation in a reconstructed patient

March 10, 2016

1. Fibrous dysplasia of the mandible
2. Odontogenic keratocyst of the maxilla
3. Vertical ridge augmentation using in-situ tissue engineering and dental implants